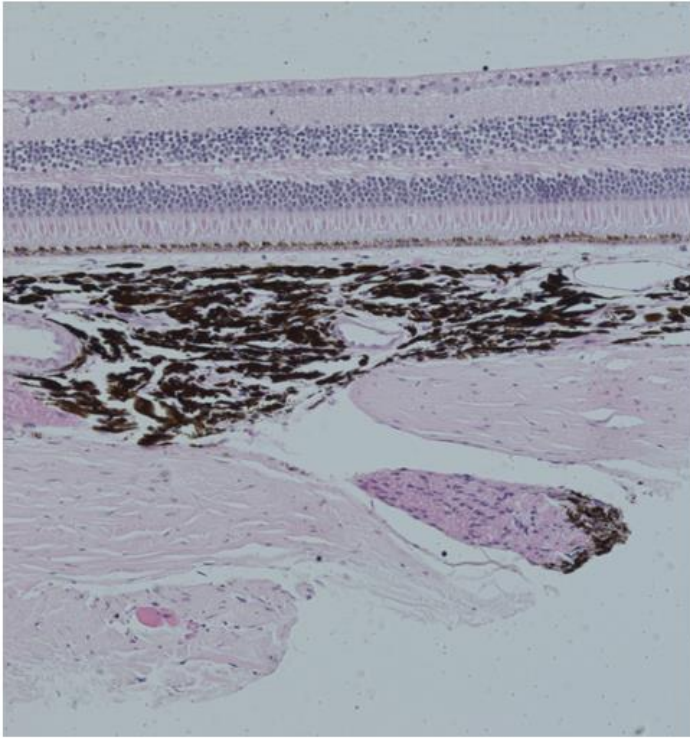
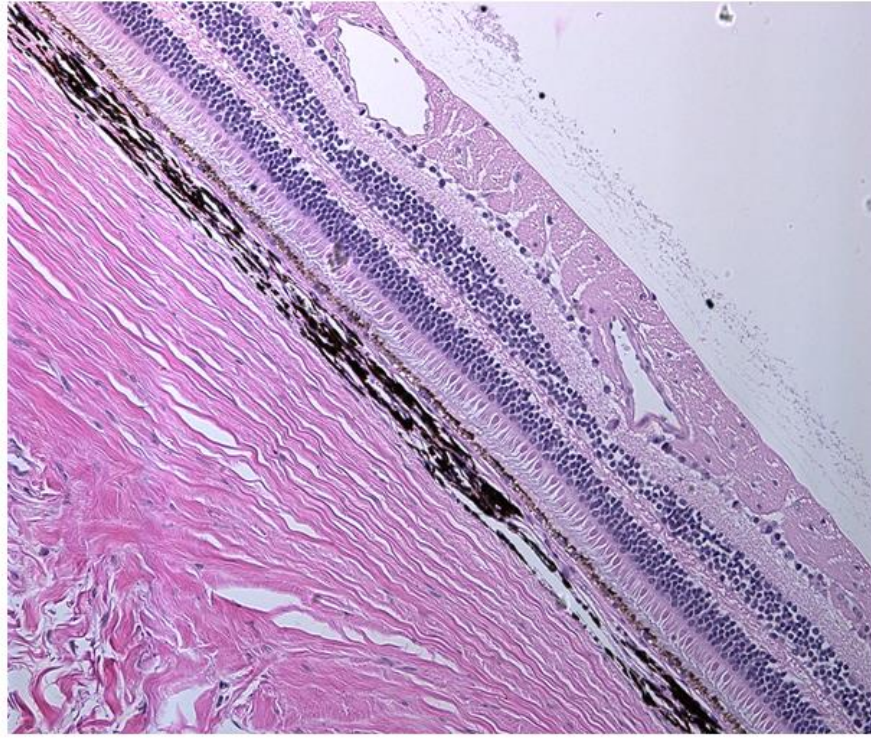


A**B**

Supplemental Figure S7. Additional H&E micrographs of animal K700-OS, 30 months post treatment with ADVN-022, in **(A)** the mid retina and **(B)** near the optic disc sections showing the preserved integrity of all retinal layers and the absence of any morphological abnormality in the retinal tissue.