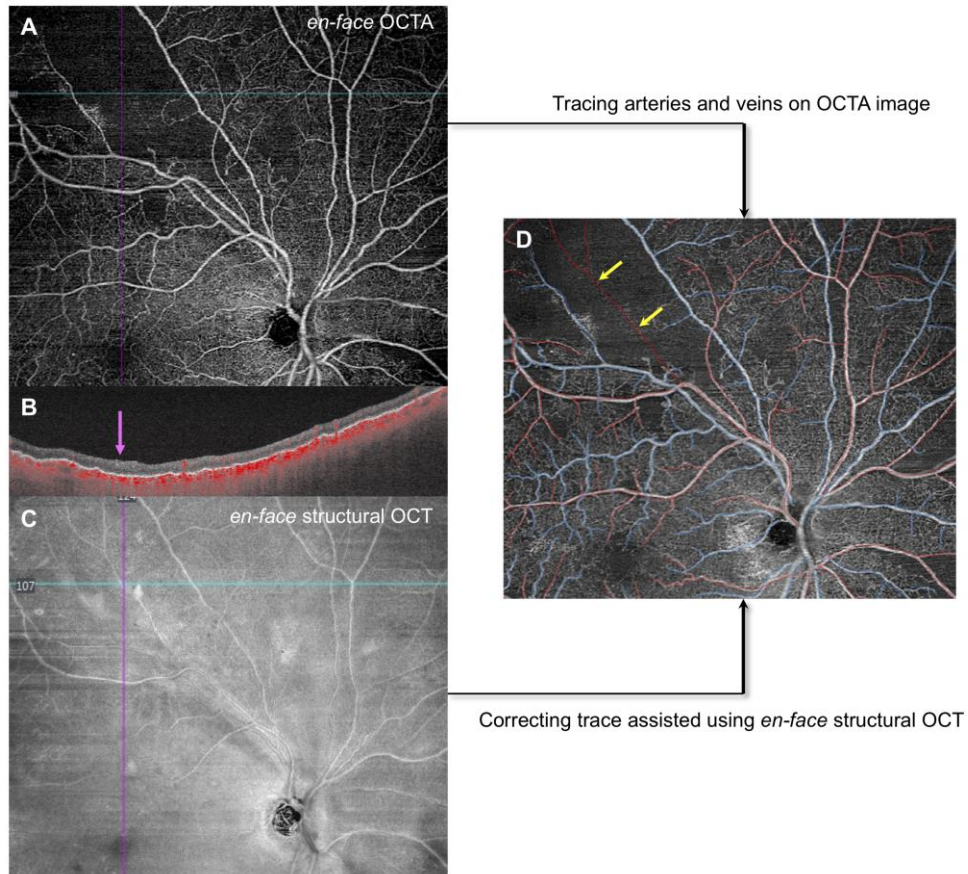


Supplemental Figure



SUPPLEMENTAL FIGURE. Correcting vascular trace assisted using en face structural OCT. **A.** The en face OCTA image shows a large capillary non-perfusion area in upper temporal retina. **B.** Flow-overlaid B-scan at the blue line in en face OCT/OCTA images reveals that a demarcated hyperintense structure representing an occluded vessel (pink arrow) can be seen without any flow signals. **C.** The en face structural OCT clearly shows an occluded second branch from the temporal retinal arteriole corresponding to the large non-perfusion area in OCTA image. **D.** Assisted by the en face structural OCT image, the occluded second branch of retinal arteriole (yellow arrows) is correctly traced on the OCTA image.